

- 22 years old ♂
- HISTORY
- Several episodes of dislocation of the RT shoulder (as the Patient said, but never been reduced by a doctor)
- Considered as subluxation rather than true dislocation.

N.P.

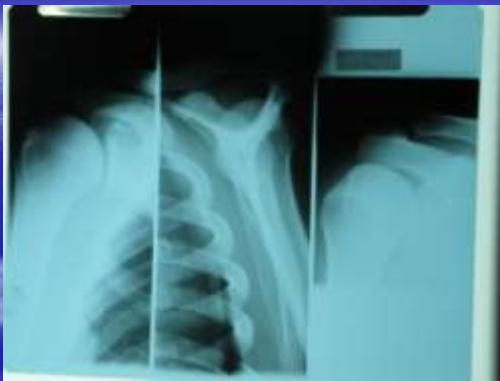1

- On Examination of his RT Shoulder:

- FROM (Active +passive)
- ↑ anteroposterior translation
- Apprehension test :+
- Dislocation/ Relocation test: +
- Sulgus test: -/+ (mild impression)

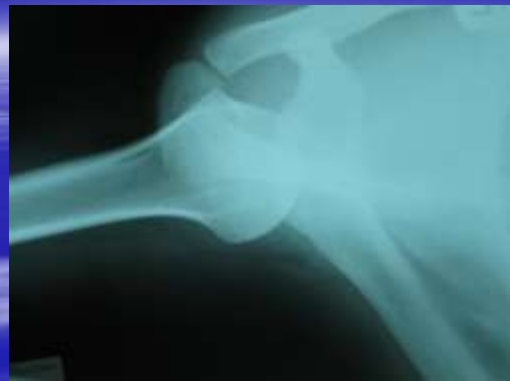N.P.

2



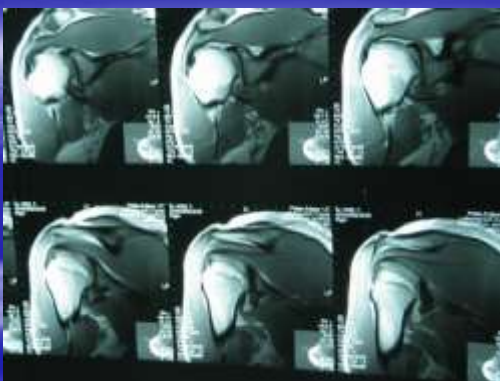
N.P.

3



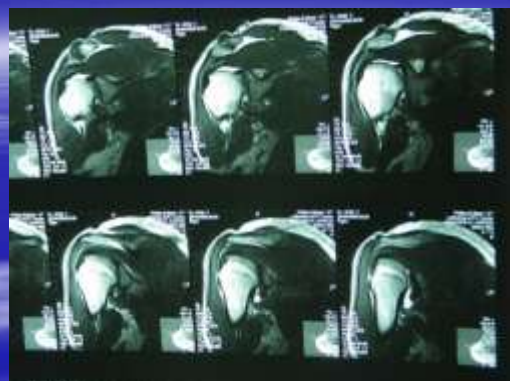
N.P.

4



N.P.

5



N.P.

6

